

संस्था को चिकित्सक सहायता हेतु आवेदन पत्र

सेवा में,

संस्थापक
चाइल्ड सेवा ट्रस्ट
टी-53/4, सब्जी मंडी,
रेलवे कॉलोनी
नई दिल्ली 110007



भारत सरकार
Government of India



TAKHE TARI
Father : Takhe Puna
DOB : 24/04/1982
Male



4614 0609 8357

विषय : संगठन के संस्थापक को चिकित्सक सहायता संबंधित अनुरोध पत्र।

महोदय जी,

“सविनय निवेदन यह है कि प्रार्थी ताखे तारी
का निवासी हूँ। मेरे बच्चे का नाम ताखे सायु जिसका आयु 6 है।

जिसका इलाज AML, गांग्राना रोग होस्पिटल में चल रहा है, मेरा
बच्चा ल्यूकेमिया ब्लड कैंसर से पीड़ित है, बच्चे की चिकित्सक स्थिति संबंधित विवरण”

मेरे बच्चे को ब्लड कैंसर के इलाज के लिए बाइओ परसी टेस्ट, किमो थेरेपी, SDP Kit
बोन मरो ट्रांसप्लांट के साथ-साथ इंजेक्शन और दवाइयों की बहुत जरूरत है।

हमारा परिवार बच्चे का इलाज करवाने हेतु आर्थिक रूप से सक्षम नहीं है एवं बच्चे की
वर्तमान स्थिति के अनुसार बच्चे को सुचारु इलाज की शीघ्र आवश्यकता है।

प्रार्थी चाइल्ड सेवा ट्रस्ट से अनुरोध करता / करती हूँ कि आप मेरे बच्चे के इलाज में
हमें आर्थिक सहायता प्रदान करें।

मैं अपनी सहमति से बच्चे के इलाज से संबंधित सभी चिकित्सक आलेख आपसे साझा
कर रहा / रही हूँ जिससे आपको मेरे बच्चे की वर्तमान चिकित्सक स्थिति से अवगत करवाया
जा सके।

मैं और मेरा परिवार चाइल्ड सेवा ट्रस्ट एवं आप से जुड़े सभी दाताओं का दिल से
आभारी रहेगा / रहूंगी।

धन्यवाद!

अभिभावक

हस्ताक्षर

अंगूठे का निशान

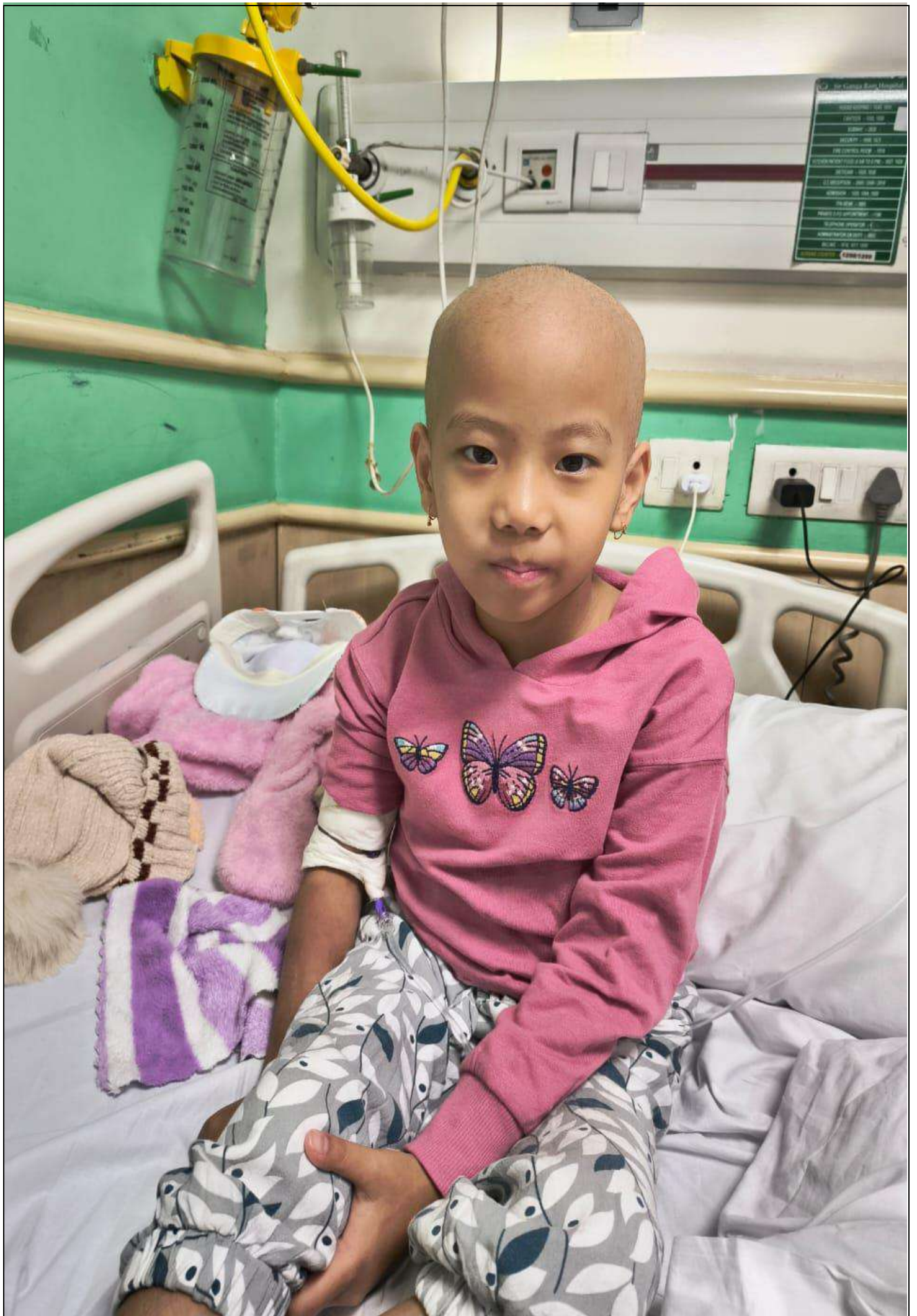
ताखे तारी



संस्थापक

आपका अनुरोध चाइल्ड सेवा
ट्रस्ट द्वारा स्वीकार्य है

यह प्रारूप परिवार की से शैक्षिक स्थिति एवं कोविड-19 को ध्यान में रखते हुए तैयार
किया गया है, किसी प्रकार की त्रुटि के लिए संस्था क्षमा व्यापक है।



DEPARTMENT OF PAEDIATRIC HEMATO
DISCHARGE SUMMARY

Patient Name 814 Ms Takhe Apu Episode No. 190 IP01437568

CBC showed Hb 9.1%, TLC 15710/cumm, Plt 2000/cumm, ANC 99/cumm, AMC - 170/cumm.

At present child is stable, accepting orally and is discharged with advice to follow up in E-Block on 18/11/24 with CBC/DLC in E-Block 3015 or SOS in ward 9 if fever occurs

PROCEDURES: Bone marrow aspiration and biopsy, LP with TIT

REORTS AWAITED: TP1 MRD, Bone marrow aspiration and biopsy, CSF for malignant cells

DISCHARGE ADVICE

- Syp Crocin DS (5ml/240mg) 5 ml SOS if pain
- Remove bone marrow dressing tomorrow.
- Tab Voriconazole(200) 1 - 0 - ½ to continue
- Tab Septran (969 mg) ½ - 0 - ¼ (Mon, wed, Friday) to continue
- Laxopeg sachet twice daily to continue OR

Muout Plus Powder 1 scoop thrice daily for constipation

- Candid mouth paint 4 drops thrice a day to continue
- Chlorhexidine mouth wash thrice daily to continue
- Sitz bath thrice daily
- Avoid raw fruits, salads
- Plenty of oral fluids, No visitors, Strict hygiene
- To maintain genital hygiene and general hygiene
- Don't administer any vaccination to the child/ Avoid OPV to the family member

FOLLOW UP

- To follow up with CBC/DLC on 15/11/24 in E Block 3015 or SOS in ward 9 if fever occurs
- To follow with Dr. Anupam Sachdeva/ Dr. Manas Kalra

- Reports of investigations done during hospital stay are provided on a separate sheet
- Pending reports can be collected from "CIC-Room no. 32, ground floor (9AM-5PM)
- Histopathology Reports, Blocks or Extra Slides can be collected from Lab 1st Floor SSRB on all working days between 9 AM - 5 PM
- Contact no. of Emergency: 011-42251098, 42251099 Contact no. of SGRH Telephone Exchange: 011-42254000, 25750000
- Home Care Service: "REACH OUT" services like Nursing Care, Sample Collection, Injections, X-rays, Physiotherapy, Dressing, Nutrition and Diet Counselling etc. are available in the comfort of your home.

Laxente
Resident Doctor

Consultant

Consultant Paediatric Hemato-Oncology

Paediatrics

Indusind Bank

SIR GANGA RAM HOSPITAL

Sir Ganga Ram Hospital Bldg
Wazirpur, New Delhi

DATE: 16/11/2024 TIME: 10:53:04
MID: INDB000009155964
TID: pos. 11344476@indus
INVOICE NO: 5026957 525068 241116
105306

Sale
PAYMENT MODE: QR
PAYMENT METHOD: Indusind Bank
RIN: 432151619912
TOTAL AMT: INR 10000.00

SIGNATURE NOT REQUIRED
I AGREE TO PAY AS PER
TERMS & CONDITIONS

THANK YOU
PLEASE VISIT AGAIN
***** CUSTOMER COPY *****
Version 1.0.69
Powered by Payswiff

Sir Ganga Ram Hospital

WAZIR NAGAR, NEW DELHI-110060

PHONE: 011-42254000 (30 Lines); 011-35125600 (30 Lines); Fax: 25861002
TIN No.: 07AABTS4366E1ZH, HOSPITAL PAN No.: AABTS 4366E

ADVANCE RECEIPT

Receipt No : 2024-11/112971

Date : 16/11/2024

HE APU

Received an amount of Rs. 10000 (Rupees Ten Thousand only) in the name of MS TAKHE APU towards Advance by UPI No 43215169912 dated 16/11/2024 via CASH INDUSLAND BANK 25113320

Rs 10000/-

For Sir Ganga Ram Hospital



(Accounts Officer)

1. As per the Govt. Notification, Cash Rs 2 lakh and above can not be accepted
2. For Cancellation / Refund of the Bill, any identity Proof - Photo ID, Aadhar Card, Pan Card, Driving License, Passport is mandatory



PEDIATRIC AND ADOLESCENT HEMATOLOGY, ONCOLOGY & STEM CELL TRANSPLANT SERVICES

Sir Ganga Ram Hospital, Rajinder Nagar, New Delhi - 110060

Dr. Anupam Sachdeva

DCH, MD, (DMC No. : 11823)
Adjunct Professor, National Board of Examination
President Indian Academy of Pediatrics 2017
Director
Chairman, Department of Pediatrics
Private OPD, Room No F-3015, SGRH
Timing : 12 Noon - 4 PM, Mon - Sat

Dr. (Prof.) Manas Kalra

MBBS (Gold Medalist), MD (Gold Medalist), DNB
FNB (Pediatric Hematology Oncology), FIAP
Fellowship Pediatric Oncology & BMT (Sydney)
Senior Consultant
(DMC No. : 35631)
Private OPD : Room No. F-3015, SGRH
Timing : 12 Noon - 4 PM, Mon - Sat

15/11/24

~~SPRASHOOP~~
Takhe Apu

HT = 112.2 cm
WT = 18.4 kg

CBC - 7.6 / 2800 / 45,000 /
952 / 56

Δ - AML
post Induction cycle ①
MRD - 24% Blasts ⊕

C/S/B Dr. Manas Kalra

Rx Admit in ped-SP

- 1) FLAG - cycle ① chemo to be given.
- 2) Send SQPT, creat.

Shivani



H-2008-0017
Since June 16, 2008



Sir Ganga Ram Hospital

MOLECULAR HEMATOLOGY

Department of Hematology

Phone : 011-42251853, 54

E-mail: molhematsgrh@gmail.com

Lab Ref No. : A51/24
Patient's Name : Takhe Apu
Age/Sex : 06Y/F
Consultant/Unit : Dr. Anupam Sachdeva

Date Collected : 10/10/2024
Date Received : 10/10/2024
Date Reported : 14/10/2024
Regn. No : 3445246
Ward/OPD : IPD

Clinical History: Bone marrow (BM-933/24) suggestive of Acute Myeloid Leukemia.

Test Name: AML-PCR PANEL

Qualitative RT-PCR for AML1::ETO translocation

Specimen: Bone Marrow in EDTA.

Results: The test sample is found to be **Negative** for AML1::ETO fusion transcript.

Interpretation: The AML1::ETO or t(8;21) fusion transcript, created by the reciprocal translocation of AML1 gene on 21q22 and ETO gene on 8q22. It is detected in about 5-12% of AML and implies a relatively good prognosis.

Qualitative RT-PCR for Inversion-16 Translocation

Specimen: Bone Marrow in EDTA.

Results: The test sample is found to be **Negative** for Inversion 16 translocation.

Interpretation: The pericentric inversion of chromosome 16 (inv16), involves CBFβ gene on 16p13.1 and the MYH11 gene on 16q22 and gives CBFβ::MYH11 fusion transcript. It is detected in about 1-5% of AML cases and is associated with favorable prognosis

Page 1/2



H-2008-0017
Since June 16, 2008



Sir Ganga Ram Hospital

MOLECULAR HEMATOLOGY
Department of Hematology
Phone : 011-42251853, 54
E-mail: molhematsgrh@gmail.com

Lab Ref No. : A51/24
Patient's Name : Takhe Apu
Age/Sex : 06Y/F
Consultant/Unit : Dr. Anupam Sachdeva

Date Collected : 10/10/2024
Date Received : 10/10/2024
Date Reported : 14/10/2024
Regn. No : 3445246
Ward/OPD : IPD

Clinical History: Bone marrow (BM-933/24) suggestive of Acute Myeloid Leukemia.

Test Name: AML-PCR PANEL

Qualitative RT-PCR for AML1::ETO translocation

Specimen: Bone Marrow in EDTA.

Results: The test sample is found to be **Negative** for AML1::ETO fusion transcript.

Interpretation: The AML1::ETO or t(8;21) fusion transcript, created by the reciprocal translocation of AML1 gene on 21q22 and ETO gene on 8q22. It is detected in about 5-12% of AML and implies a relatively good prognosis.


Qualitative RT-PCR for Inversion-16 Translocation

Specimen: Bone Marrow in EDTA.

Results: The test sample is found to be **Negative** for Inversion 16 translocation.

Interpretation: The pericentric inversion of chromosome 16 (inv16), involves CBFB gene on 16p13.1 and the MYH11 gene on 16q22 and gives CBFB::MYH11 fusion transcript. It is detected in about 1-5% of AML cases and is associated with favorable prognosis

Page 1/2



H-2008-0017
Since June 16, 2008



MC - 2194

Clinical Laboratory Services
Department of Haematology

Name	: MS TAKHE APU	Age/Sex	: 6 Yrs/Female
Registration No.:	3445246	Ward No.	:
Lab Request No.:	1124217226	Room No.	:
Episode No.	: OP14264876	Location Type:	Out Patient
Location	: B1 CENTRAL INVESTIGATION CENTRE	Collected On	: 04 NOV 2024 11:22AM
Referred By	: Dr. Manas Kalra	Received On	: 04 NOV 2024 12:28PM
Ext. Doctor	:	Reported On	: 04 NOV 2024 04:55PM
Specimen	: Blood	Released by	: Dr. Swati
Printed on	: 11 NOV 2024 05:54PM		

Investigation	Results	Units	Bio.Ref.Interval	Test Method
---------------	---------	-------	------------------	-------------

CBC shows pancytopenia.
Leucopenia with neutropenia is seen.
Platelets are reduced, counted on smear.

Kindly correlate with clinical and treatment profile of the patient.

1. This is a Computer generated report, No Signature required.
2. Content of this report is only an opinion, not the diagnosis.
3. The report shall not be reproduced, except in full, without permission.

<<< Page: 2 of 2 >>>



Sir Ganga Ram Hospital



H-2008-0017
Since June 16, 2008



MC - 2194

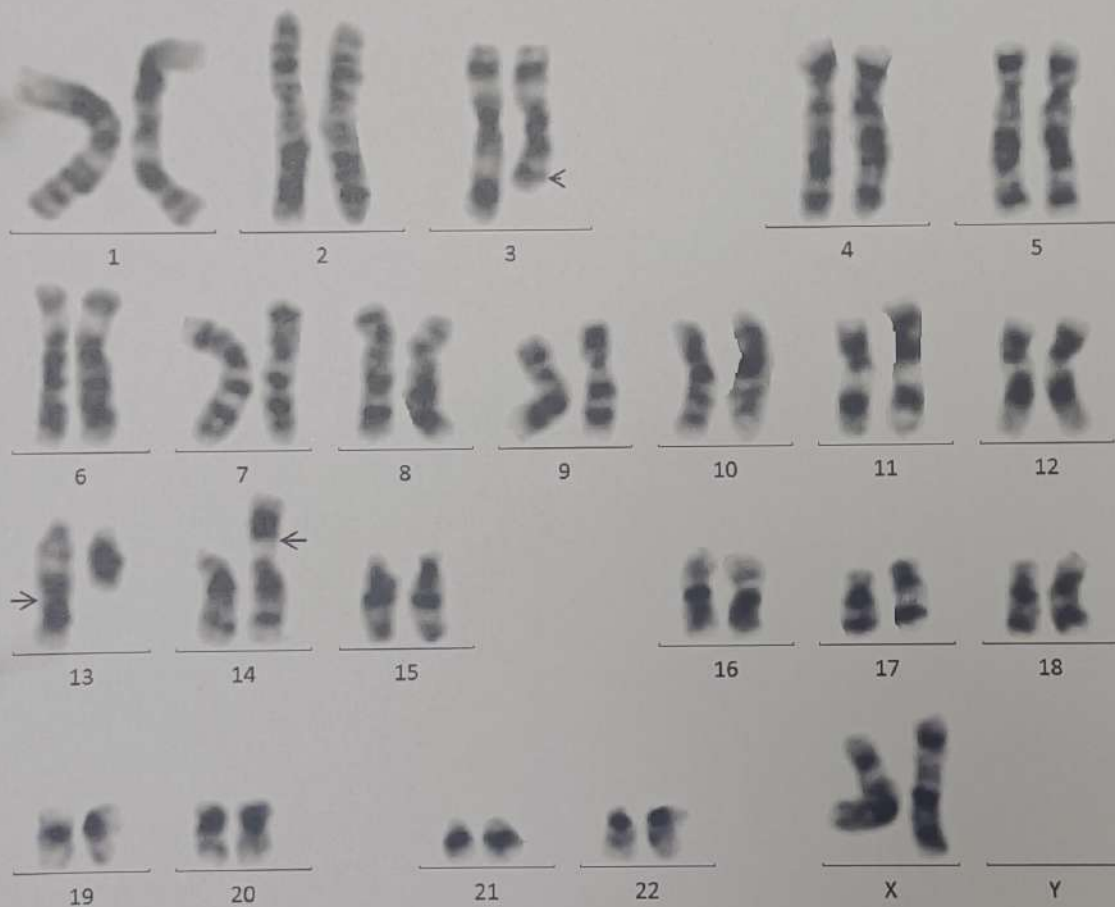
Institute of Medical Genetics and Genomics Computerised Karyotype analysis

Lab No. : BMI 5036-24

Name : TAKHE APU

Sample: Bone marrow

Karyotype of metaphase no.1



Final Karyotype Report: 46,XX,t(3;13)(q22;q32),t(13;14)(q14;p11.2)[8]/46,XX[12]

No. of Metaphases counted and karyotyped : 20

Culture technique used: Short term harvest technique with GTG banding

Band resolution: 300-400 band level (ISCN 2020)





H-2008-0017
Since June 16, 2008



Sir Ganga Ram Hospital

MOLECULAR HEMATOLOGY
Department of Hematology
Phone : 011-42251853, 54
E-mail: molhematsgrh@gmail.com

Lab Ref No. : AS1/24
Patient's Name : Takhe Apu
Age/Sex : 06Y/F
Consultant/Unit : Dr. Anupam Sachdeva

Date Collected : 10/10/2024
Date Received : 10/10/2024
Date Reported : 14/10/2024
Regn. No : 3445246
Ward/OPD : IPD

Clinical History: Bone marrow (BM-933/24) suggestive of Acute Myeloid Leukemia.

Test Name: AML-PCR PANEL

Qualitative RT-PCR for AML1::ETO translocation

Specimen: Bone Marrow in EDTA.

Results: The test sample is found to be **Negative** for AML1::ETO fusion transcript.

Interpretation: The AML1::ETO or t(8:21) fusion transcript, created by the reciprocal translocation of AML1 gene on 21q22 and ETO gene on 8q22. It is detected in about 5-12% of AML and implies a relatively good prognosis.

Qualitative RT-PCR for Inversion-16 Translocation

Specimen: Bone Marrow in EDTA.

Results: The test sample is found to be **Negative** for Inversion 16 translocation.

Interpretation: The pericentric inversion of chromosome 16 (inv16), involves CBFB gene on 16p13.1 and the MYH11 gene on 16q22 and gives CBFB:MYH11 fusion transcript. It is detected in about 1-5% of AML cases and is associated with favorable prognosis.

Page 1/2



PAN No : AACTC8249B

CHILD SEWA TRUST

"YOU CAN RELY ON US"

Khasra No. 337-F, Gali No. 8 Ram Park Extn., Loni Dehat,
.P.-201102

Ref. No.84.....

Dated30.11.2024.....

चाइल्ड सेवा ट्रस्ट द्वारा आर्थिक चिकित्सक सहायता प्रदान करने पश्चात प्राप्त स्वीकृत सर्वनाम लेखन पत्र

चाइल्ड सेवा ट्रस्ट संस्था के माध्यम से आपके बच्चे तारखे अप्पु जिसकी ..
6 वर्ष है तारखे तारी के निवेदन के आधार पर आपके बच्चे की
चिकित्सक स्थिति एवं आपके द्वारा प्राप्त चिकित्सक साक्ष्यों के आधार पर बच्चे की वर्तमान
चिकित्सक स्थिति एवं परिवार की आर्थिक स्थिति को देखते हुए संस्था चाइल्ड सेवा ट्रस्ट
द्वारा आपके बच्चे के सुचारु इलाज के लिए आर्थिक सहायता प्रदान की जा रही है।

आशा करते हैं संस्था कि इस छोटी से पहल के द्वारा आपके बच्चे का इलाज
सुव्यवस्थित ढंग से हो पाएगा

अतः संस्था अपने सभी दाताओं के सहयोग से सदैव आपको इसी प्रकार आर्थिक अनुदान
सहायता प्रदान करती रहेगी एवं सदैव आपके साथ है

अभिभावक

हस्ताक्षर

अंगूठे का निशान



संस्थापक
चाइल्ड सेवा ट्रस्ट